



Veterinary Cancer Care, P.C.

2001 Vivigen Way

Santa Fe, NM 87505

www.vetcancercare.com

Phone: (505) 982-4492 Fax: (505) 982-1701 info@vetcancercare.com

ORAL TUMORS - FIBROSARCOMAS AND RELATED TUMORS

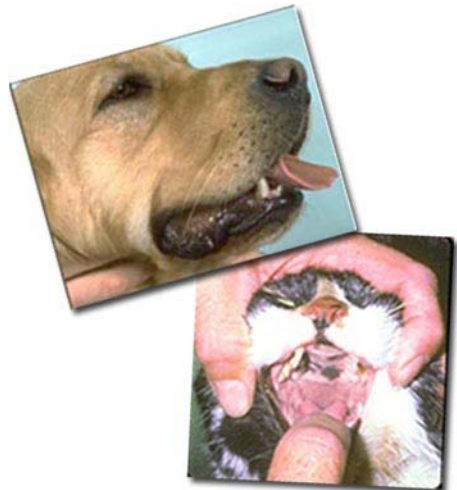These notes are provided to help you understand the diagnosis or possible diagnosis of cancer in your pet. For general information on cancer in pets ask for our handout "What is Cancer". Your veterinarian may suggest certain tests to help confirm or eliminate diagnosis, and to help assess treatment options and likely outcomes. Because individual situations and responses vary, and because cancers often behave unpredictably, science can only give us a guide. However, information and understanding for tumors in animals is improving all the time.

We understand that this can be a very worrying time. We apologize for the need to use some technical language. If you have any questions please do not hesitate to ask us.

What are these tumors?

Oral **fibrosarcomas** are rapidly growing, malignant tumors originating from the fibrous connective tissue of the mouth. The tumors are rarely cured by surgical removal. Recurrence in the mouth and spread to other parts of the body (metastasis) are common.

A few of these cancers have numerous 'giant cells' that have many instead of one nucleus. These tumors are called '**giant cell tumors**'. They behave like fibrosarcomas and frequently recur although they rarely metastasize. The tissue origin is uncertain. A rare cancer of the blood vessels, '**epithelioid angiosarcoma**', occurs around the tooth roots. It is too rare to be certain about behaviour but it will probably be similar to fibrosarcoma.



What do we know about the cause?

The reason why a particular pet may develop this, or any cancer, is not straightforward. Cancer is often seemingly the culmination of a series of circumstances that come together for the unfortunate individual.

Cancer is a genetic disease of somatic cells with "external" contributory factors such as chemical, physical and traumatic. The mutated cells upset the normal regulation of cell death and replacement. They do this by activating growth-promoting oncogenes (cancer genes), inactivating suppressor genes and altering the genes that regulate normal, programmed cell death (apoptosis).

Why has my pet developed this cancer?

Some animals have a greater tendency (genetic susceptibility) to cancer and some breeds have far more of these cancers than others.

Oral fibrosarcomas in cats are not caused by feline sarcoma virus (FeSV), but feline leukemia virus (FeLV) may contribute to their development.

Are they common tumors?

In dogs, oral fibrosarcomas represent between 17 percent and 26 percent of all mouth tumors. Some types occur in young animals, even less than a year of age. A quarter of these tumors are recorded in dogs less than five years of age. Larger dogs, particularly Golden Retrievers, are more predisposed to develop the tumors than smaller breeds. Tumors are also more common in male dogs than in bitches. Most are on the gums with equal numbers in the upper and lower jaws. They can occur on the palate and even, occasionally, in the tongue.

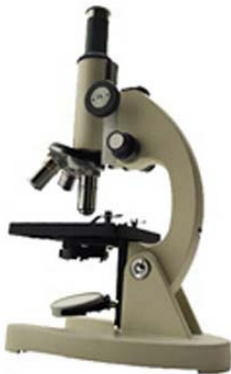Oral fibrosarcomas are the second most common mouth tumors in cats but they still only represent approximately one in ten oral tumors. There is no breed or sex predilection. The average age of affected cats is 13 years but they may occur as early as one year of age.

How will this cancer affect my pet?

These tumors are usually noticed as swellings on the gums that frequently ulcerate and bleed and may become secondarily infected. Other common clinical signs include drooling saliva, difficulty in eating, displacement or loss of teeth and facial swelling. There may be pain and swelling of the local lymph nodes (glands).

How is this cancer diagnosed?

Clinically, malignant oral tumors often have a fairly typical appearance. X-rays may be useful in detecting whether tumors have invaded the bones and to guide surgery. Loss of bone adjacent to the tumor usually means a poorer outlook (prognosis) because malignant gum tumors destroy bone whereas benign ones tend to make the adjacent bone grow.




Cytology, the microscopic examination of cell samples, is not diagnostic for these tumors. Definitive diagnosis, prediction of behavior (prognosis) and a microscopic assessment of whether the tumor has been fully removed rely on microscopic examination of tissue (histopathology). This is done at a specialized laboratory by a veterinary pathologist. The piece of tissue may be a small part of the mass (biopsy) or the whole lump but only examination of the whole lump will indicate

whether the cancer has been fully removed. Histopathology also rules out other cancers.

Most of these tumors invade the bone of the jaw. They need wide surgical margins usually including substantial parts of the jaw bone. This type of tissue will need decalcifying so it may take a few weeks before the final histopathology results are available.

What types of treatment are available?

Surgical removal is the standard method of treatment for all these tumors. The invasive cancers are difficult to remove completely so large pieces of the jaw bone may be removed (hemimaxillectomy or hemimandibulectomy). The complex and extensive surgery is often done at a referral treatment center.



Scalpel

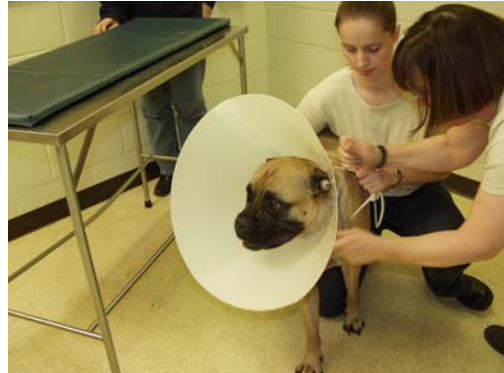Fibrosarcomas do not respond to chemotherapy and response to radiotherapy is only palliative. However, one subtype, diagnosable as a separate entity at early stages and called maxillary fibrosarcoma responds to radiation hyperthermia therapy.

Can this cancer disappear without treatment?

Curing infections and healing ulcers will help reduce superficial swelling but not cure the cancer. Very occasionally, spontaneous loss of blood supply to the cancer can make parts of it die but the dead tissue will still need surgical removal. The body's immune system is not effective at making these tumors to regress.

How can I nurse my pet?

After surgery, you will probably be provided with an "Elizabethan collar" to prevent your pet from interfering with the operation site. You may be requested not to examine the surgery but inability to eat or significant swelling or bleeding should be reported to your veterinarian. Your pet may require a special diet. If you require additional advice on post-surgical care, please ask.



How will I know how this cancer will behave?

Histopathology will give your veterinarian the diagnosis that helps to indicate how it is likely to behave. The veterinary pathologist usually adds a prognosis that describes the probability of local recurrence or metastasis (distant spread). The completeness of excision will be assessed and other diagnoses ruled out.

When will I know if the cancer is permanently cured?

'Cured' has to be a guarded term in dealing with any cancer.

In dogs, survival after local surgical removal is sometimes as short as one month before recurrence necessitates euthanasia. Major, radical surgery can result in tumor-free time as long as 32 months but the median survival is only seven months, and only about one half of cases will survive beyond one year. Fibrosarcomas closer to the front of the mouth are usually easier to treat so have a better prognosis.

A cancer called "undifferentiated sarcoma of palatine origin" is a separate subgroup that occurs near the upper carnassial (large back) teeth in large breeds less than 4 years of age. This cancer is particularly aggressive and life expectancy is shorter than for other fibrosarcomas.

Maxillary fibrosarcoma may respond to radiation hyperthermia therapy.

In cats, there are usually surgical complications post-operatively and survival is often only a few months. Tumors at the front of the mouth, and not crossing the midline if they are in the upper jaw, have the best outlook.

Are there any risks to my family or other pets?

No, these are not infectious tumors and are not transmitted from pet to pet or from pets to people.