



VETERINARY  
cancer care

Veterinary Cancer Care, P.C.  
2001 Vivigen Way  
Santa Fe, NM 87505  
www.vetcancercare.com

Phone: (505) 982-4492 Fax: (505) 982-1701 info@vetcancercare.com

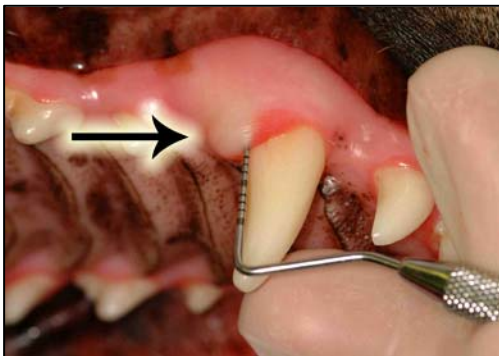
## ORAL TUMORS - EPULI, BASAL CELL CARCINOMAS AND AMELOBLASTOMAS

These notes are provided to help you understand the diagnosis or possible diagnosis of cancer in your pet. For general information on cancer in pets ask for our handout "What is Cancer". Your veterinarian may suggest certain tests to help confirm or eliminate diagnosis, and to help assess treatment options and likely outcomes. Because individual situations and responses vary, and because cancers often behave unpredictably, science can only give us a guide. However, information and understanding for tumors in animals is improving all the time.

We understand that this can be a very worrying time. We apologize for the need to use some technical language. If you have any questions please do not hesitate to ask us.

### ***What are these tumors?***

An **epulis** (plural epuli) is the clinical name for a swelling on the gums. Several different tumors share this name, often of different origins including the tooth-socket lining and lining epithelium of the mouth. Most epuli are not cancerous but overgrowths (hyperplasias) as a reaction to trauma. These are fibrous ('fibrous hyperplasia' or '**fibromatous epulis**'). If they are more active, often with bone formation, they are called '**peripheral odontogenic fibroma**' (POF) or '**fibromatous and ossifying epulis**'). These originate from the tooth forming tissue. A few of this type are cancerous but benign. Occasionally, these become more malignant and invade locally. Rarely, there is spread to lymph nodes (glands) as fibrosarcomas.



Epulis

Image courtesy of Ian J. Haws, DVM, FAVD,  
Dip. AVDC,  
Ontario Veterinary College

Cancers that are more aggressive and invade the bone of the jaws include basal cell carcinomas that originate from the epithelium of the gum surface and a tumor of tooth (odontogenic) epithelium called '**ameloblastoma**' or '**adamantinoma**'. There are other types of very rare tumors that arise from the

tooth tissues (including amyloid-producing 'odontogenic' or '**calcifying epithelial odontogenic**' tumor). These other tumors tend to recur after surgery.

### ***What do we know about the cause?***

The reason why a particular pet may develop this, or any cancer, is not straightforward. Cancer is often seemingly the culmination of a series of circumstances that come together for the unfortunate individual.

Most epuli are hyperplasias (overgrowth) as a reaction to trauma. Cancer is a genetic disease of somatic cells with “external” contributory factors such as chemical, physical and traumatic. The mutated cells upset the normal regulation of cell death and replacement. They do this by activating growth-promoting oncogenes (cancer genes), inactivating suppressor genes and altering the genes which regulate normal, programmed cell death (apoptosis).

### ***Why has my pet developed this cancer?***

Some animals have a greater tendency (genetic susceptibility) to cancer. Some breeds have far more cancers than others, often of specific types. Multiple extensive gingival hyperplastic lesions occur mainly in Boxers and other short-nosed breeds.

### ***Are these common tumors?***

The non-cancerous epuli are common in older dogs but rare in cats. Some dogs, particularly Boxers and other short-nosed dogs have multiple growths called ‘gingival hyperplasia’. This is present in almost a third of Boxers. Basal cell carcinomas are far less common. Ameloblastomas are unusual in dogs and even rarer in cats. They can occur at any age.

### ***How will these tumors affect my pet?***

These tumors are usually noticed as swellings on the gums that frequently ulcerate and bleed and may become secondarily infected. Other common clinical signs include drooling saliva, difficulty in eating, displacement or loss of teeth and facial swelling. Epuli are rarely painful.

### ***How are these tumors diagnosed?***

Clinically, the tumors often have a fairly typical appearance. X-rays may be useful in detecting whether tumors have invaded the bones and to guide surgery. Loss of bone adjacent to the tumor usually means a poorer outlook (prognosis) because malignant gum tumors destroy bone whereas benign ones tend to make the adjacent bone grow.

Cytology, the microscopic examination of small cell samples, is not diagnostic for these tumors. Definitive diagnosis, prediction of behavior (prognosis) and a microscopic assessment of whether the tumor has been fully removed rely on microscopic examination of tissue (histopathology). This is done at a specialized laboratory by a veterinary pathologist. The piece of tissue may be a small part of the mass (biopsy) or the whole lump but only examination of the whole lump will indicate whether the cancer has been fully removed. Histopathology also rules out other cancers.

60% of epuli have bone in them. Although this does not affect behavior, the tissue may need decalcifying before a final report on the tumor can be given, delaying results. Tumors that invade the bone will need wide surgical margins including substantial parts of the jaw bones so it may take a few weeks before the final histopathology results are available.

### ***What types of treatment are available?***

Surgical removal is the standard treatment for all these tumors. The invasive cancers are difficult to remove completely so large pieces of the jaw bone may be removed (hemimaxillectomy or hemimandibulectomy). Dogs (particularly when young) respond well to this radical surgery. This complex and extensive surgery is often done at a referral treatment centre.

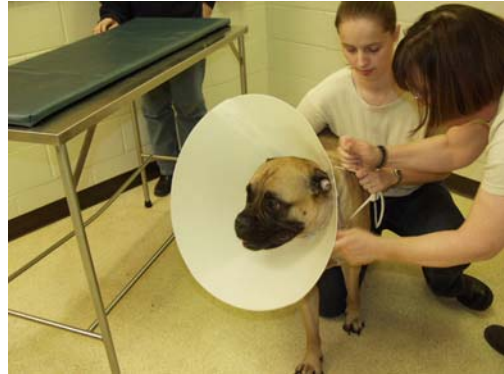### ***Can these cancers disappear without treatment?***

The reactions to trauma can reduce in size if the stimuli are removed. Curing infections and healing ulcers will help. Very occasionally, spontaneous loss of blood supply to the cancer

can make parts of it die but the dead tissue will still need surgical removal. The body's immune system is not effective at making these tumors to regress.

### ***How can I nurse my pet?***

After surgery, you will probably be provided with an "Elizabethan collar" to prevent your pet from interfering with the operation site. You may be requested not to examine the surgery but inability to eat or significant swelling or bleeding should be reported to your veterinarian. Your pet may require a special diet. If you require additional advice on post-surgical care, please ask.



### ***How will I know how these tumors will behave?***

Histopathology will give your veterinarian the diagnosis that helps to indicate how the tumor is likely to behave. The veterinary pathologist usually adds a prognosis that describes the probability of local recurrence or metastasis (distant spread). The completeness of excision will be assessed and other diagnoses ruled out.

### ***When will I know if the cancer is permanently cured?***

'Cured' has to be a guarded term in dealing with any cancer.

Epuli rarely recur if the cause of the proliferation and inflammation is removed. A few of the most active ones do regrow and require more extensive surgery. This may be indicated in the histopathology report.

Basal cell carcinomas recur in about half the cases with significant bone destruction and tooth loss. Ameloblastomas also tend to recur and invade and destroy bone. Both will need extensive surgery for complete cure but they do not metastasize to other parts of the body. Survival for more than a year is not uncommon after radical surgery.

A mildly cautious outlook is usually suggested for all these tumors because they can be multiple. Occasionally the clinically apparent lump is above a different and more malignant tumor and a few epuli will progress to more invasive types. However, most gingival growths are benign.

### ***Are there any risks to my family or other pets?***

No, these are not infectious tumors and are not transmitted from pet to pet or from pets to people.