



VETERINARY  
cancer care

Veterinary Cancer Care, P.C.

2001 Vivigen Way

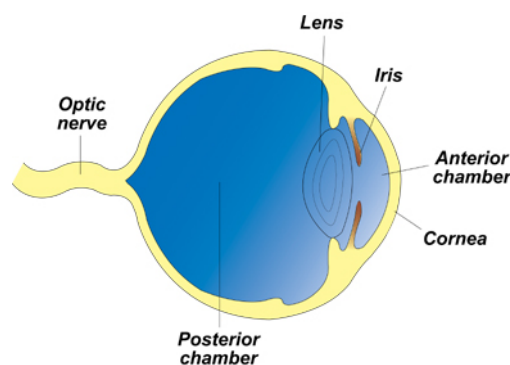
Santa Fe, NM 87505

www.vetcancercare.com

Phone: (505) 982-4492 Fax: (505) 982-1701 info@vetcancercare.com

## EYE TUMORS - MELANOMAS IN DOGS

### *Structure of the eye and melanocyte biology*



Melanocytes are cells that produce a pigment called melanin. They are found in many parts of the body where there is pigment, particularly the skin, hair and eyes. In embryonic development, melanocytes are related to cells of the nervous system. Melanogenesis (formation of melanin) is a complex process with genetic, hormonal and ultraviolet (UV) control. A suntan is the result of stimulation of these cells by sunlight (UVA and UVB). Inside the eye melanocytes are found in the iris and choroid layers (see diagram).

These notes are provided to help you understand the diagnosis or possible diagnosis of cancer in your pet. For general information on cancer in pets ask for our handout "What is Cancer". Your veterinarian may suggest certain tests to help confirm or eliminate diagnosis, and to help assess treatment options and likely outcomes. Because individual situations and responses vary, and because cancers often behave unpredictably, science can only give us a guide. However, information and understanding for tumors in animals is improving all the time.

We understand that this can be a very worrying time. We apologize for the need to use some technical language. If you have any questions please do not hesitate to ask us.

### ***What are these tumors?***

Melanocytic tumors are formed by abnormal melanocytes. Melanocytoma is a benign (non-spreading) melanoma. Malignant (spreading) tumors are sometimes called 'melanoma' or more specifically "malignant melanoma" or "melanosarcoma".

The most common tumors originate from the iris (anterior uvea) [see diagram]. They are usually benign. Eyelid, conjunctival, limbal and choroid tumors are all rare. Only conjunctival tumors are malignant. Limbal tumors are nodules that can be removed surgically. The anterior uveal and choroid tumors are usually benign but cause problems by increasing the intra-ocular pressure (glaucoma) that leads to blindness.

### ***What do we know about the cause?***

The reason why a particular pet may develop this, or any cancer, is not straightforward. Cancer is often seemingly the culmination of a series of circumstances that come together for the unfortunate individual.

In humans, environmental and host factors are important in development of melanoma. In dogs, tumors are most frequent in heavily pigmented animals.

### ***Why has my pet developed this cancer?***

The genetic make up of your dog or heavy pigmentation is likely to be the main predisposing factor. 'Diffuse uveal melanosis' is a clinically distinct presentation in Cairn Terriers.

### ***Are these common tumors?***

Melanomas are common in dogs. Anterior uveal melanocytomas are the most common intra-ocular tumor in dogs. More rarely, the tumors are found in other parts of the eye. They include limbal tumors, arising from the line of melanocytes at the junction between cornea and sclera, choroid tumors, conjunctival melanoma and the very rare diffuse uveal melanosis.

### ***How will these cancers affect my pet?***

Primary conjunctival tumors may cause redness and weeping from the eye before the lump is visible. This is painful. Limbal tumors are protruding black nodules at the corneo-scleral junction. They have a smooth periphery.

The benign intra-ocular tumors are slow-growing masses that eventually bulge into the vitreous. Some become large and eventually cause uveitis (inflammation), glaucoma (increased ocular pressure), retinal detachment or optic nerve compression. All these will result in blindness. Small tumors may not be causing clinical disease at the time of diagnosis.

### ***How are these cancers diagnosed?***

Clinically, these tumors are usually visible with an ophthalmoscope. Not all are pigmented and other types of tumors may also be pigmented or look dark so accurate diagnosis of the type of tumor relies upon microscopic examination of tissue. Various degrees of surgical sampling may be needed including cellular aspirates, biopsies and full excision. Irises can be sampled by the vacuum technique for rapid diagnosis by cytology (the microscopic examination of cell samples). This assesses the need for surgery after which tumors may undergo microscopic examination of tissue (histopathology). This enables accurate diagnosis and prediction of behavior (prognosis). Histopathology is done at a specialized laboratory by a veterinary pathologist.

The histopathology report indicates the type of tumor and mitotic rate (which is important to predict life expectancy). The pathologist may need to remove (bleach) the pigment to check for malignancy with greater certainty.

### ***What types of treatment are available?***

In dogs, melanocytic tumors arising in different parts of the eye show different behavior and need different treatment. Conjunctival tumors are usually malignant so full surgical removal



Ophthalmoscope

From: Equine Ophthalmology  
by DE Brooks  
Published by Teton  
NewMedia  
With permission

is the treatment of choice. Limbal tumors are protruding black nodules at the corneo-scleral junction. They have a smooth peripheral growth pattern so are good candidates for surgical excision without removing the eye. Most other tumors require more extensive surgery. As in humans, there has been little progress with other treatments.

### ***Can these cancers disappear without treatment?***

Cancer very rarely disappears without treatment. Very occasionally, spontaneous loss of blood supply to the cancer can make it die but the dead tissue will still need surgical removal. The body's immune system is not effective in causing these tumors to regress.

### ***How can I nurse my pet?***

After surgery, an "Elizabethan collar" may be provided to prevent your pet rubbing his or her eye and interfering with the operation site. This needs to be kept clean. Any loss of stitches or significant swelling or bleeding should be reported to your veterinarian.



Specific treatment may include eye drops and ointments with antibiotics and anti-inflammatory drugs.

If you require additional advice on post-surgical care, please ask.

### ***How will I know how the cancer will behave?***

Histopathology will give your veterinarian the diagnosis that helps to indicate how it is likely to behave. The veterinary pathologist usually adds a prognosis that describes the probability of local recurrence or metastasis (distant spread).

### ***When will I know if the cancer is permanently cured?***

'Cured' has to be a guarded term in dealing with any cancer.

Melanomas arising from the conjunctiva are malignant and both recur at the site and metastasize even if histologically they appear benign. It is difficult to promise complete cure once your dog has developed this type of tumor.

Anterior uveal tract melanocytomas and choroidal and limbal melanocytomas are usually benign. The few malignant tumors arising from the anterior uvea can be recognized histologically. Only about 5% of tumors metastasize.

Limbal tumors have a smooth surface so can often be cured by surgical excision without removal of the eye.

Benign intra-ocular tumors are still clinically significant as they spread within the globe and cause glaucoma and uveitis. Canine diffuse uveal melanosis causes blindness.

### ***Are there any risks to my family or other pets?***

No, these are not infectious tumors and are not transmitted from pet to pet or from pets to people.