



VETERINARY  
cancer care

Veterinary Cancer Care P.C.  
2001 Vivigen Way  
Santa Fe, NM 87505  
www.vetcancercare.com

Phone: (505) 982-4492 Fax: (505) 982-1701 [info@vetcancercare.com](mailto:info@vetcancercare.com)

## MAST CELL TUMORS IN CATS

These notes are provided to help you understand the diagnosis or possible diagnosis of cancer in your pet. For general information on cancer in pets ask for our handout "What is Cancer". Your veterinarian may suggest certain tests to help confirm or eliminate diagnosis, and to help assess treatment options and likely outcomes. Because individual situations and responses vary, and because cancers often behave unpredictably, science can only give us a guide. However, information and understanding for tumors in animals is improving all the time.

We understand that this can be a very worrying time. We apologize for the need to use some technical language. If you have any questions please do not hesitate to ask us.

### ***What is this tumor?***

This is a tumor originating from the body's mast cells. The tumors include both benign (non-spreading) and malignant (life-threatening, spreading) types. Many are multiple. Recurrence of some tumors is possible but spread to other parts of the body (metastasis) is unusual.

### ***Mast cell biology***

Mast cells originate in the bone marrow but complete their development in peripheral tissues. They are found in all tissues of the body but are concentrated in the skin, respiratory tract and digestive tract. Mast cells interact with cells of the immune (protective) system producing allergic type antibodies (IgE), presenting foreign molecules (antigens) to immune system cells and recruiting certain cells (phagocytes) to engulf foreign or invading material. As well as being a cellular barrier to external agents, mast cells have a regulatory function on cutaneous nerves, blood circulation, fibrous tissue and other immune cells. They are therefore important in allergic responses, tissue remodelling, wound healing and non-allergic skin diseases. Mast cells in hair follicles also help to regulate the cyclical activity of those follicles.

Not surprisingly, with all these functions, mast cells are not a single cell type.

### ***What do we know about the cause?***

The reason why a particular pet may develop this, or any cancer, is not straightforward. Cancer is often seemingly the culmination of a series of circumstances that come together for the unfortunate individual.

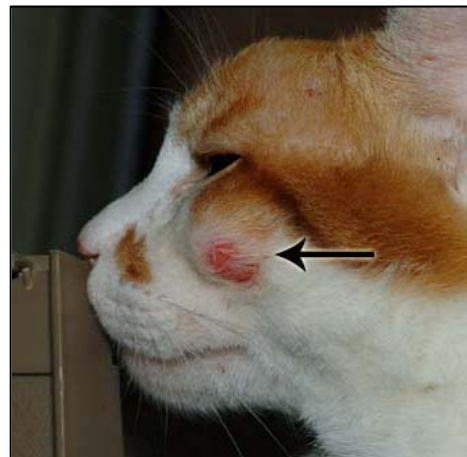


Image courtesy of Jan Hall, BVM&S, MS, MRCVS, DipACVD, Clinical Dermatology, Ontario Veterinary College

The cause of this tumor in cats is unknown. For humans, research has indicated that abnormalities of certain receptors (key-lock mechanisms) on the surface of mast cells may contribute to some of these tumors. Other causes are overproduction of body factors that

stimulate mast cell proliferation (such as Stem Cell factor, SCF); and cellular genetic mutations and gene malfunctions. Details of these are beyond the scope of these notes.

### ***Is this a common tumor?***

Mast cell tumors are less common in cats than in dogs although cats have more mast cells in the skin compared with dogs. Cats with mast cell tumors are usually over four years of age but any age can be susceptible including kittens. The tumors often occur at multiple sites within the same cat but most are benign (non-life-threatening, non-spreading). Occasionally mast cell tumors involve internal organs such as liver, spleen and lungs.

Mast cell tumors are particularly common in Siamese cats and this breed has a specific variant called the **histiocytic mast cell tumor**.

### ***How will this cancer affect my pet?***

Most mast cell tumors are noted as firm plaques or nodules (small lumps) in the skin. There may be itching because the tumors produce substances that induce inflammation.

Weight loss due to loss of body fat and muscle may occur in cancer that has spread and there may be illness secondary to production of inflammatory substances by the tumor.

### ***How is this cancer diagnosed?***

Pre-surgical microscopic examination of small samples of cells (cytology) from the tumor can help to identify some mast cell tumors. More accurate diagnosis and assessment of excision margins (the borders between tumor and surrounding normal healthy tissues) relies upon microscopic examination of the whole tumor (histopathology), which is done at a specialized laboratory by a veterinary pathologist.

The histopathology report typically includes words that indicate whether a tumor is 'benign' (non-spreading, local growth) or 'malignant' (life-threatening, capable of spreading to other body sites). This, together with the origin or type of tumor, the grade (degree of resemblance to normal cells or 'differentiation') and stage (how large it is and extent of spread) indicate how the cancer is likely to behave. The information from the whole lump will indicate whether the cancer has been fully removed.

### ***What types of treatment are available?***


Surgery is the routine first treatment whenever possible. Treatments with drugs (chemotherapy) or radiation are of uncertain outcome, have side effects and are only used after careful consideration and discussion.

Gastrointestinal side effects of the mast cell tumor can be treated symptomatically with hydrogen ion receptor antagonists such as cimetidine, or calcium channel blockers such as omeprazole.

### ***Can this cancer disappear without treatment?***

Some mast cell proliferations are not neoplastic but are temporary overgrowths (hyperplasia) and may disappear even when they are present in lymph nodes. Cats also have large numbers of mast cells in some inflammatory reactions. These are not neoplastic but they can cause severe urticaria (wheals, rash) and pruritus, which are poorly responsive to treatment. Young related Sphinx cats have also been diagnosed with skin infiltrations of mast cells associated with pruritic papules (very small lumps) and plaques.

Well-differentiated multiple tumors in kittens (sometimes known as "mastocytosis") regress spontaneously. Mastocytosis may be a hyperplasia. Occasionally (even at a few weeks of



age), there are hundreds of similar lesions. The behavior of multiple tumors in older cats is uncertain.

Histiocytic mastocytomas in Siamese cats are often multiple and regress spontaneously.

Poorly differentiated mast cell tumors do not disappear spontaneously.

### ***How can I nurse my pet?***

Preventing your cat from rubbing, scratching, licking or biting the tumor will reduce itching, inflammation, ulceration, infection and bleeding. Any ulcerated area needs to be kept clean.

After surgery, the operation site similarly needs to be kept clean and your pet should not be allowed to interfere with the site. Any loss of sutures or significant swelling or bleeding should be reported to your veterinarian. If you require additional advice on post-surgical care, please ask.

### ***When will I know if the cancer is permanently cured?***

‘Cure’ has to be a guarded term in any cancer. Absence of recurrence or spread for more than 6 months after surgery is a favorable sign.



Histopathology will give your veterinarian the diagnosis of tumor type and status that helps to indicate how the tumor is likely to behave. The veterinary pathologist usually adds a prognosis that describes the probability of local recurrence or metastasis (distant spread).

Well-differentiated, benign, solitary mast cell tumors are cured by surgical removal, even in elderly cats. However, there is a tendency for cats to develop multiple, apparently primary, sequential mast cell tumors, some of which are benign and some not. Multiple tumors disappear within a few months in young cats but the situation in older cats is less certain.

Some feline mast cell tumors have features indicating potential malignancy. Multiple tumors are common and the tumors usually recur or spread to other sites in 2 to 3 months. Tumors often involve the lymph nodes but do not necessarily spread to internal organs or other sites. The presence of tumors in the internal organs does not necessarily imply metastasis from a cutaneous site; many arise *de novo*. The precise features that are most prognostic for malignant behavior are still uncertain.

Histiocytic mast cell tumors are usually found in young Siamese cats and they regress spontaneously within two years but then can recur in multiple crops of 1/8 – ¼ inch nodules.

### ***Are there any risks to my family or other pets?***

No, these are not infectious tumors and are not transmitted from pet to pet or from pet to people.