



Veterinary Cancer Care, P.C.

2001 Vivigen Way

Santa Fe, NM 87505

www.vetcancercare.com

Phone: (505) 982-4492 Fax: (505) 982-1701 info@vetcancercare.com

## HAIR FOLLICLE TUMORS

These notes are provided to help you understand the diagnosis or possible diagnosis of cancer in your pet. For general information on cancer in pets ask for our handout "What is Cancer". Your veterinarian may suggest certain tests to help confirm or eliminate diagnosis, and to help assess treatment options and likely outcomes. Because individual situations and responses vary, and because cancers often behave unpredictably, science can only give us a guide. However, information and understanding for tumors in animals is improving all the time.

We understand that this can be a very worrying time. We apologize for the need to use some technical language. If you have any questions please do not hesitate to ask us.

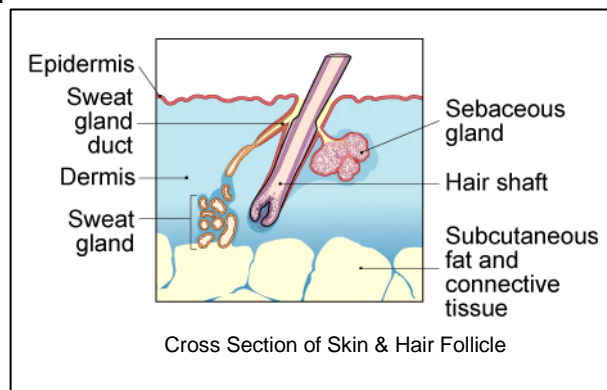
### ***What is this tumor?***

This is one of many similar tumors that arise by disordered growth of the hair follicles. These tumors are almost all benign and can be permanently cured by total surgical removal. Some occur at multiple sites within the same animal.

This family of tumors grade into each other. Precise nomenclature is usually irrelevant as almost all are benign.

### ***What do we know about the cause?***

The reason why a particular pet may develop this, or any cancer, is not straightforward. Cancer is often seemingly the culmination of a series of circumstances that come together for the unfortunate individual.



B-catenin is required for differentiation of skin cells into hair follicles. If there is over-production of this chemical in the body, hair follicle tumors develop. There is a genetic predisposition for these tumors to develop in certain breeds of dog.

### ***Is this a common tumor?***

These are common tumors in some breeds of dog (see below).

The infundibular keratinizing acanthoma (synonyms are: intracutaneous cornifying epithelioma, keratinizing epithelioma, keratoacanthoma) arises from the upper part of the follicle (infundibulum) so may have a pore opening onto the surface. These tumors may be solitary or multiple. They are mainly found on the back of the neck and trunk. The discharge is keratin (similar to the skin's outermost layer), often with pus or blood because inflammation and secondary infection are common. Average age of affected animals is 5

years with a predominance in male animals. The Norwegian Elkhound and Keeshound are predisposed to multiple tumors.

The closely related trichoepithelioma is often multiple in German Shepherd dogs. They are usually in middle-aged dogs but can occur in puppies. They may ulcerate and discharge pus and blood.

Trichoblastomas originate from hair matrical cells and are the most common type of follicular tumor in the cat. The rare tricholemmomas develop from the middle or lower segment of the follicle. There are numerous histological patterns for these tumors, but none of clinical significance.

Pilomatrixomas (also known as pilomatrixoma, or the necrotizing and calcifying epithelioma of Malherbe) are hair matrical tumors, seen in dogs. They are usually solitary. The Kerry Blue, Poodle, Bedlington Terrier, Bichon Frise, Schnauzer and other breeds with continuous hair growth have higher susceptibility because of the greater mitotic (cell division) activity of their hair follicles, which are in the growth phase (anagen) for longer. There is an extremely rare malignant form.

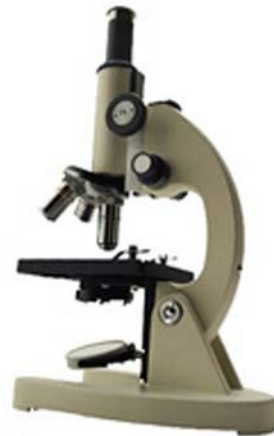### ***How will this tumor affect my animal?***

The main problems are physical because of the size and site of the tumor. Many superficial tumors ulcerate, ooze unpleasant blood-stained fluid and become secondarily infected.

The very rare, multiple, malignant form of pilomatrixoma may spread throughout the body, often very rapidly and before the primary tumor is noted as a significant problem.

### ***How is this tumor diagnosed?***

Clinically, one of these tumors is often suspected. Accurate diagnosis relies upon microscopic examination of tissue. Needle aspirates for cytology (microscopic examination of cell samples) is not diagnostic for these tumors. Diagnosis, prediction of behavior (prognosis) and assessment of whether the tumor has been fully removed rely on microscopic examination of surgically removed tissue from the suspect tumor (histopathology). This is done at a specialized laboratory by a veterinary pathologist. Histopathology also rules out other cancers.



### ***What types of treatment are available?***

Treatment is usually surgical removal of the lump.

Multiple infundibular keratinizing acanthomas have been treated surgically, followed by antibiotics, clipping the entire hair coat and high doses of omega-3-fatty acids (fish oil). Other anti-cancer drug treatments are expensive with potentially dangerous side effects.

### ***Can this tumor disappear without treatment?***

Tumors very rarely disappear without treatment. Very occasionally, spontaneous loss of blood supply to the cancer can make it die but the dead tissue will still need surgical removal or it will weep and smell. The body's immune system is not effective in causing this type of tumor to regress.

### ***How can I nurse my pet?***

Preventing your pet from rubbing, scratching, licking or biting the tumor will reduce itching, inflammation, ulceration, infection and bleeding. Any ulcerated area needs to be kept clean.

After surgery, the operation site similarly needs to be kept clean and your pet should not be allowed to interfere with the site. Any loss of sutures or significant swelling or bleeding should be reported to your veterinarian. If you require additional advice on post-surgical care, please ask.

### ***How will I know if the tumor is permanently cured?***

'Cured' has to be a guarded term in dealing with any tumor.

Histopathology will give your veterinarian the information that will help to indicate how the tumor is likely to behave. The veterinary pathologist usually adds a prognosis that indicates the probability of local recurrence or metastasis (distant spread).



Almost all these tumors are benign. They are cured by surgical excision. Some animals have multiple tumors so further tumors may develop at different sites.

If a trichoepithelioma is described as malignant, it is only of low-grade malignancy and unlikely to recur. They do not spread elsewhere.

The very rare, multiple, malignant form of pilomatricoma is usually recognized very early as it spreads through the body and causes clinical illness.

### ***Are there any risks to my family or other pets?***

No, these are not infectious and are not transmitted from pet to pet or from pets to people.