



Veterinary Cancer Care, P.C.

2001 Vivigen Way

Santa Fe, NM 87505

www.vetcancercare.com

Phone: (505) 982-4492 Fax: (505) 982-1701 info@vetcancercare.com

## FELINE FIBROSARCOMA AND SARCOID

These notes are provided to help you understand the diagnosis or possible diagnosis of cancer in your pet. For general information on cancer in pets ask for our handout "What is Cancer". Your veterinarian may suggest certain tests to help confirm or eliminate diagnosis, and to help assess treatment options and likely outcomes. Because individual situations and responses vary, and because cancers often behave unpredictably, science can only give us a guide. However, information and understanding for tumors in animals is improving all the time.

We understand that this can be a very worrying time. We apologize for the need to use some technical language. If you have any questions please do not hesitate to ask us.

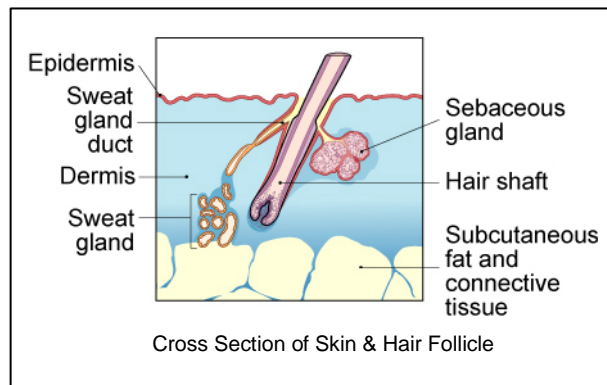
### ***What is this tumor?***

**Fibrosarcoma** is a tumor originating from the fibroblasts of the skin and subcutaneous connective tissue. The tumors vary in growth rate. They often recur locally although spread to other parts of the body (metastasis) is rare. The **feline sarcoïd** is a subtype of tumor that is caused by a papilloma (wart) virus.

### ***What do we know about the cause?***

The reason why a particular pet may develop this, or any cancer, is not straightforward. Cancer is often seemingly the culmination of a series of circumstances that come together for the unfortunate individual.

Feline sarcoma retroviruses (recombinant forms of feline leukemia virus - FeLV) may initiate fibrosarcoma development in young cats and where there are multiple tumors in cats of more than five years of age. The virus disrupts the genome and causes chromosomal changes. Most older cats have immunity to the virus so, in older cats, solitary sarcomas are not usually FeLV-virus associated.



There is currently controversy about the cause of tumors arising in the shoulder and neck area. Some of these may be due to previous tissue damage. Tumors apparently at vaccination sites and more particularly where rabies vaccine and certain adjuvants (substances in the vaccines to increase their potency) had been given, started to appear in occasional cats in the USA in the 1990's. No viruses have been found in these tumors and one suggestion has been that the adjuvant might be acting as the carcinogen in certain susceptible cats. The tumors have different and specific pathology in the international

classification. In Europe, GREFFI (Groupe d'Etudes des Fibrosarcomes Felins) was founded because of the controversy on the possibility of vaccine-associated tumors. This group has found that, in France at least, the peak age for tumors is now younger than previously with a bimodal distribution with peaks at 6-7 and 10-11 years. In the UK, the Veterinary Medicines Directorate collects reports on adverse reactions to vaccines but their data has not confirmed any definite vaccine link for fibrosarcomas. It is suggested that in individual cats factors other than injection may be prerequisites for fibrosarcoma formation.

The feline sarcoid (fibropapilloma) is due to a papilloma virus infection.

### ***Is this a common tumor?***

Fibrosarcoma is the most common malignant soft tissue cancer in the cat. There is genetic heterogeneity of fibrosarcoma cells so there is also variable tumor behavior. Many grow rapidly. Predilection sites used to be the shoulder, ears and feet. Almost 50% are now between the shoulder blades or on the back of the neck with 25% on the chest and flanks. Lower leg and foot tumors are now rare. The incidence of possible vaccine-related tumors in the USA is very low and currently not increasing.

Solitary skin sarcoid in cats is a rare condition reported in young cats. They are usually on the upper lip but may be on the hind legs.

### ***How will this cancer affect my pet?***

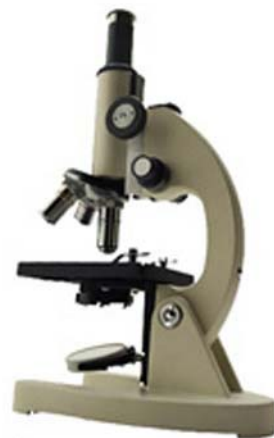The most obvious effect is a lump. This is often painful but ulceration and bleeding are less common. There may be physical effects on surrounding structures. Although it is unusual for these cancers to spread to distant parts of the body (metastasize), they are locally invasive.

A history of sudden swelling is sometimes noted with tumors of the leg. It suggests that growth is insidious until lymphatic return is inhibited or the growth affects the nerves.

"Sarcoids" are usually solitary nodules on the upper lip but may also be on hind legs. The associated lymph node may swell.

### ***How is this cancer diagnosed?***

This tumor can often be tentatively diagnosed on clinical examination. In order to positively identify the tumor, it is necessary to obtain a sample of the tumor itself. Cytology is the microscopic examination of cell samples but it is difficult to obtain an adequate number of cells from this type of tumor. The surgical margins and rate of cell division (mitotic index) are the important factors in prognosis (assessment of future behaviour) so histopathology (microscopic examination of specially prepared and stained tissue sections) is necessary for diagnosis. This is done at a specialized laboratory where the slides are examined by a veterinary pathologist. The examination of the whole tumor will also indicate whether the tumor has been completely removed.



### ***What treatment is available?***

Treatment is surgical removal of the lump. The tumors do not respond well to either radiotherapy or chemotherapy. Cats with tumors that allow a better margin of excision usually have a better prognosis.

The incidence of possible vaccine-related tumors is very low and not increasing so small post-vaccination, inflammatory nodules (granulomas) are not removed unless they start to grow or persist for a long period.

### ***Can this cancer disappear without treatment?***

Cancer rarely disappears without treatment but as development is a multi-step process, it may stop at some stages. Rarely, loss of blood supply to a cancer will make it die but the dead tissue will probably need surgical removal.

As older cats tend to be immune and resist viral tumor development, regression of virally induced sarcoids can occur.

### ***How can I nurse my pet?***

Preventing your pet from rubbing, scratching, licking or biting the tumor will reduce itching, inflammation, ulceration, infection and bleeding. Any ulcerated area needs to be kept clean.

After surgery, the operation site similarly needs to be kept clean and your pet should not be allowed to interfere with the site. Any loss of sutures or significant swelling or bleeding should be reported to your veterinarian. If you require additional advice on post-surgical care, please ask.



### ***How / When will I know if the cancer is permanently cured?***

'Cured' has to be a guarded term in dealing with any cancer.

Histopathology will give your veterinarian the diagnosis that helps to indicate how it is likely to behave. The veterinary pathologist usually adds a prognosis that describes the probability of local recurrence or metastasis (distant spread).

The prognosis of fibrosarcomas depends on the location (for ease and margin of excision), duration of the tumor and grade as determined by frequency of cell divisions (mitotic index). Tumor associated deaths (two-thirds in three years) are due to primary site recurrence (more than two-thirds) with approximately ten to fifteen percent metastasizing. Tumors in very young cats (approximately one year of age) tend to be more malignant.

Feline sarcoids are usually on the nose or face. Surgical removal usually cures them but recently local recurrence has been reported.

### ***Are there any risks to my family or other pets?***

No, although some of these tumors have a viral origin, they are not transmissible from pet to pet or to people by contact or through body fluids.

---

*This client information sheet is based on material written by Joan Rest, BVSc, PhD, MRCPATH, MRCVS.  
© Copyright 2004 Lifelearn Inc. Used with permission under license. December 19, 2008.*