



VETERINARY
cancer care

Veterinary Cancer Care, P.C.

2001 Vivigen Way

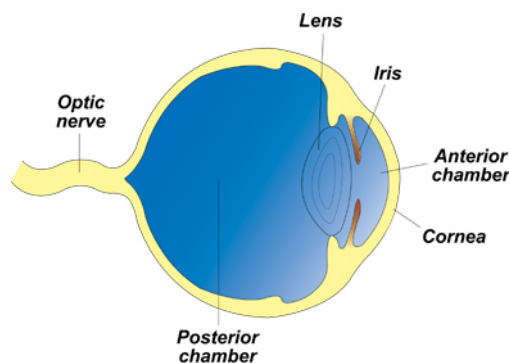
Santa Fe, NM 87505

www.vetcancercare.com

Phone: (505) 982-4492 Fax: (505) 982-1701 info@vetcancercare.com

TUMORS OF THE EYELIDS, CONJUNCTIVA AND PERI-OCULAR TISSUES

Structure of the eye

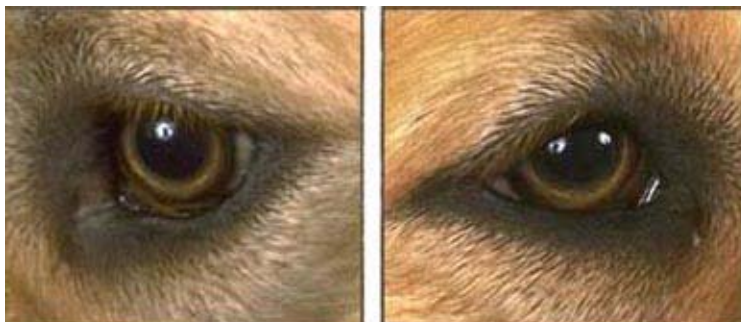

These notes are provided to help you understand the diagnosis or possible diagnosis of cancer in your pet. For general information on cancer in pets ask for our handout "What is Cancer". Your veterinarian may suggest certain tests to help confirm or eliminate diagnosis, and to help assess treatment options and likely outcomes. Because individual situations and responses vary, and because cancers often behave unpredictably, science can only give us a guide. However, information and understanding for tumors in animals is improving all the time.

We understand that this can be a very worrying time. We apologize for the need to use some technical language. If you have any questions please do not hesitate to ask us.

What are these tumors?

A "tumor" is a lump. Most, but not all, are cancerous. A large number of different types of tumor, with a bewildering array of names, but often of confusingly similar appearance, can occur in association with the tissues around the eye.



Tumors that occur on the haired eyelids are similar to those arising elsewhere in the skin. They include cysts, overgrowths (hyperplasias), benign (non-spreading) and occasionally malignant (spreading) cancers. Tumors may originate from the

sebaceous (Meibomian) glands, sweat glands (glands of Moll) and from cells such as those which produce melanin pigment, mast cells and the covering epithelium. Many Meibomian tumors rupture to cause nodules of inflammation called chalazions.

Some tumors that occur on the third eyelid and conjunctiva are similar to those elsewhere, for example those arising from the covering epithelium (particularly squamous cell carcinomas), melanin producing cells (melanomas), blood vessels and lymphoid tissue (lymphosarcomas or lymphomas). Tumors specific for this site include cysts and malignant tumors of the glands and an inflammatory condition called 'nodular granulomatous episcleritis' (nodular fasciitis).

Tumors of the adjacent orbital tissues include those originating in the tear (lachrymal) glands and connective tissue, including that of the brain envelope (meninges).

What do we know about the cause?

The reason why a particular pet may develop this, or any cancer, is not straightforward. Cancer is often seemingly the culmination of a series of circumstances that come together for the unfortunate individual.

Squamous cell carcinoma and blood vessel tumors are related to exposure to sunlight. Papillomas in this site are rarely of viral origin. As some are seen over other tumors, they may be the result of trauma.

We do not know precisely what causes the other tumors but there is a genetic predisposition in some breeds of dog for Meibomian gland tumors. Chalazion is the result of rupture of an inflamed or cancerous Meibomian gland. Dermoids or choristomas and some conjunctival inclusion cysts are errors in development with epithelium trapped in the wrong site. Most conjunctival inclusion cysts are the result of mechanical implantation of surface epithelium as a consequence of surgical incision or accidental penetrating injuries.

Why has my pet developed this cancer?

Some animals have a greater tendency (genetic susceptibility) to cancer. Some breeds have far more cancers than others, often of specific types. The more divisions a cell undergoes, the more probable is a mutation so cancer is more common in older animals. In other cases, an animal has been exposed to sunlight, which causes and promotes certain cancers.

Are these common tumors?

Tumors of the Meibomian and sweat glands (cysts, hyperplasias and adenomas) are common in dogs. Chalazion is also common. Squamous cell carcinoma of the haired skin is only common in white cats, often associated with similar tumors on the nose and ears. Squamous cell carcinoma of the third eyelid is rare in cats and very rare in dogs. Vascular tumors are mainly in dogs. Melanomas of the conjunctiva are rare. Adenocarcinomas of the gland of the third eyelid are uncommon nodular swellings in old dogs (mean age 11 years). The tumors are rare in cats. Nodular fasciitis is the most prevalent primary disease of the sclera of dogs and occasionally occurs in cats. Lachrymal gland tumors are the most common type of tumor arising from the area around the eye.

How will these cancers affect my pet?

The most obvious effect of most eyelid cancers is a lump that may ulcerate, become inflamed or bleed. Most have physical effects on the eye, causing soreness, redness and weeping.

Conjunctival tumors often cause redness and weeping from the eye before the lump is visible. All inflammation of the eye is irritant and often painful. There may be infection and

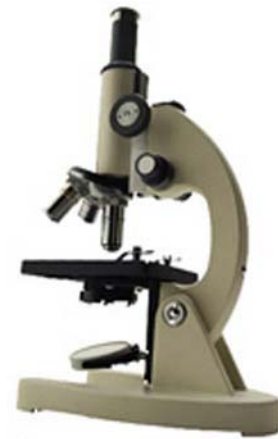pus formation. Some tumors block tear formation so the eye becomes dry ('keratoconjunctivitis sicca') and irritable. This is particularly noticeable with lachrymal gland tumors, which also cause swellings around and below the eye.

How are these cancers diagnosed?

Clinically, many of these tumors appear similar. Accurate diagnosis relies upon microscopic examination of tissue. Various degrees of surgical sampling may be needed such as smears, needle aspiration, punch biopsy and full excision. Cytology is the microscopic examination of cell samples. This is used for rapid or preliminary tests but is not diagnostic for all tumors. Full diagnosis, prediction of behavior (prognosis) and a microscopic assessment of whether the tumor has been fully removed rely on microscopic examination of tissue (histopathology). This is done at a specialized laboratory by a veterinary pathologist. The piece of tissue may be a small part of the mass (biopsy) or the whole lump but only examination of the whole lump will indicate whether the cancer has been fully removed.

What types of treatment are available?

The most common treatment is surgical removal of the lump. Malignant tumors such as squamous cell carcinoma of the conjunctiva may require removal of the whole eye. Other treatments for cysts and inflammation include anti-inflammatory agents. If there is infection, antibiotics may be indicated. Surgery is the preferred treatment for nodular fasciitis but the syndrome may respond to immunosuppressive drugs. Both nodular fasciitis and some malignant tumors may require the whole eye to be removed. Some eye surgery is very complex and specialist treatment may be needed.



Can these cancers disappear without treatment?

Some cysts and inflammation may eventually disappear without treatment but the swelling and inflammation is usually too painful to leave untreated.

Cancer very rarely disappears without treatment. Very occasionally, spontaneous loss of blood supply to the cancer can make parts of it die but the dead tissue will still need surgical removal. The body's immune system is not effective in causing these tumors to regress.

How can I nurse my pet?

After surgery, an "Elizabethan collar" may be provided to prevent your pet rubbing his or her eye and interfering with the operation site. The site needs to be kept clean. Any loss of stitches or significant swelling or bleeding should be reported to your veterinarian.

Specific treatment may include eye drops and ointments with antibiotics and anti-inflammatory drugs.

If you require additional advice on post-surgical care, please ask.

How will I know how the cancer will behave?

Histopathology will give your veterinarian the diagnosis that helps to indicate how it is likely to behave. The veterinary pathologist usually adds a prognosis that describes the probability of local recurrence or metastasis (distant spread).

When will I know if the cancer is permanently cured?

'Cured' has to be a guarded term in dealing with any cancer.

Meibomian and sweat gland cysts, hyperplasias, tumors and chalazions are usually permanently cured by surgery but all may occur in multiple glands of the eyelids so there may be further problems. Other tumors of the haired eyelid behave similarly to those in the skin.



Conjunctival inclusion cysts can be totally cured by ablation of their epithelium. The most successful medical treatment for nodular fasciitis is the use of immunosuppressive drugs but many cases still recur and infiltrate the eye, which then requires removal.

Melanomas arising from the conjunctiva are malignant, usually recur and sometimes metastasize even if they are histologically benign. They behave like tumors of this type from the mouth. Squamous cell carcinomas invade locally but metastasis to the rest of the body only occurs very late in the disease so is rare.

Adenocarcinoma of the gland of the third eyelid is a slow growing but locally infiltrative tumor that recurs unless there is complete removal of the third eyelid. Metastasis occurs only late on in the disease. This tumor is rare in cats but metastasis has been reported.

Lachrymal gland tumors are usually malignant (adenocarcinomas). They are locally invasive and often recur because of the surgical difficulty of removing them completely. Sarcomas from this site rarely metastasize but their infiltrative growth habit in this difficult site gives a poor prognosis.

Are there any risks to my family or other pets?

No, these are not infectious tumors and are not transmitted from pet to pet or from pets to people.