



VETERINARY  
cancer care

Veterinary Cancer Care, P.C.

2001 Vivigen Way

Santa Fe, NM 87505

www.vetcancercare.com

Phone: (505) 982-4492 Fax: (505) 982-1701 info@vetcancercare.com

## CYSTS

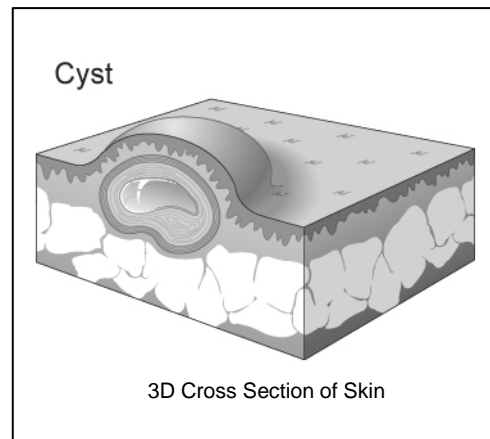
### ***What is this lump?***

**Cysts** are hollow spaces containing liquid or solidified secretion. A few cysts form within cancers but only non-cancerous cysts are considered here.

**Follicular cysts** are dilated hair follicles containing fluid or dark-colored cheesy material. They are predisposed to secondary infection (pyoderma). Sometimes they are called **epidermoid cysts**. Dilated pores and comedones (black-heads) are related to follicular cysts but have wide openings on the surface. **Dermoid cysts** are complex congenital cysts.

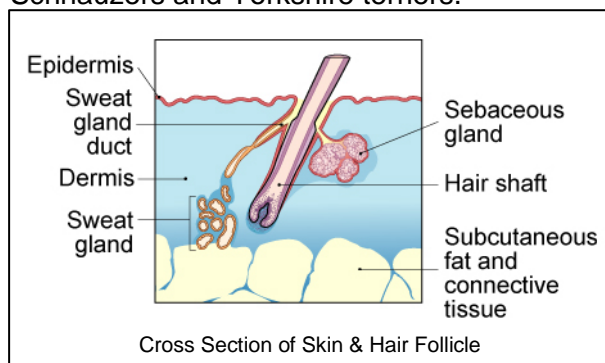
Cysts may be formed by hemorrhage or trauma leading to death of tissue and liquifaction. These are **false cysts** without a lining to produce the fluid.

**True cysts** have a secretory lining and are usually formed in glands when the ducts are blocked. Full removal or destruction of the lining may be necessary to prevent recurrence of true cysts. Examples include those formed in sweat glands.



### ***What do we know about the cause?***

Comedones and follicular cysts are secondary to local injury, blockage of the opening, mechanical or "pressure point" damage, sun radiation damage or follicular inactivity (e.g. Mexican hairless and Chinese crested dogs). Some follow treatment with drugs such as glucocorticoids ("steroids"). Others are due to loss of oily secretions in diseases such as sebaceous adenitis or there is an inherited predisposition to cysts as in breeds such as Schnauzers and Yorkshire terriers.



Comedones on the sternum and other pressure points are not uncommon in dogs with thin coats and little body fat. Multiple and recurrent follicular cysts on the heads of young dogs are a recognized entity. Boxers have a predilection for these cysts but they are also seen in other breeds.

Dermoid cysts in the midline are a failure of embryonic epidermal closure such that

isolated islands of the outer epidermal tissue remain within the deeper tissue. This is most frequent in the Rhodesian Ridgeback dog.

Cysts due to hemorrhage or trauma are common on the flank. A few are idiosyncratic reactions to injections.

### ***Why has my pet developed this tumor?***

Genetic factors favor the formation or persistence of follicular cysts in some species, particularly the dog. Some breeds having a predilection for some types as noted above.

### ***Is this a common tumor?***

Follicular cysts are common in dogs but unusual in cats except in “feline acne” on the chin and “stud tail” on the upper tail. Dermoid cysts are rare. Cysts due to trauma are moderately common in dogs. Sweat gland cysts are common in dogs and cats, particularly on the eyelids.

### ***How will these affect my pet?***

Follicular and dermoid cysts are unsightly and may discharge unpleasant, soft cheesy material (keratin). This may be infected with bacteria and yeasts and be foul-smelling.

Sweat gland cysts are nodules or vesicles, approximately 1/8 of an inch in diameter. There may be local loss of hair. They are usually slightly translucent and blue or dark in color. They may be multiple, particularly around the eyes and in the ears. Multiple tumors are sometimes called “apocrine cystadenomatosis”.

Cysts filled with blood often look dark. With the naked eye they may be difficult to distinguish from cancers.

### ***How are these diagnosed?***

Clinically, cysts are often suspected but accurate diagnosis relies upon microscopic examination of tissue. Cytology, the microscopic examination of cell samples, is not diagnostic for cysts. Accurate diagnosis and prediction of behavior (prognosis) relies upon microscopic examination of tissue (histopathology). This is done at a specialized laboratory by a veterinary pathologist. The piece of tissue may be a small part of the mass (biopsy) or the whole lump. The information from the whole lump will also indicate whether the mass has been fully removed. Histopathology can help to indicate the cause and rules out cancers.

### ***What types of treatment are available?***

The most common treatment is surgical removal of the lump. Laser treatment may be available in specialized centers and is useful for sweat gland cysts. Medical (topical) treatment of multiple small follicular cysts can be used. Other treatments may be needed to address the primary causes.

### ***Can this problem disappear without treatment?***

If the underlying cause is removed, some cysts will decrease in size or disappear. Cysts due to trauma can resolve in time.

### ***How can I nurse my pet?***

Preventing your pet from rubbing, scratching, licking or biting cysts will reduce inflammation, infection and bleeding. Any ulcerated area needs to be kept clean.



After surgery, the operation site similarly needs to be kept clean and your pet should not be allowed to interfere with the site. Any loss of sutures or significant swelling or bleeding should be reported to your veterinarian. If you require additional advice on post-surgical care, please ask.

***How will I know if there is a permanent cure?***

This depends on the cause and whether this is a single or multiple problem. In many cases, there is complete cure with excision. Multiple cysts may need investigation of the underlying cause. In cases where the cysts are a genetic characteristic (e.g. Mexican hairless dogs), there will always be a tendency to develop further cysts.

***Are there any risks to my family or other pets?***

No, these are not infectious and are not transmitted from pet to pet or from pets to people.