



Veterinary Cancer Care, P.C.

2001 Vivigen Way

Santa Fe, NM 87505

www.vetcancercare.com

Phone: (505) 982-4492 Fax: (505) 982-1701 info@vetcancercare.com

## CALCIUM DEPOSITS IN THE SKIN (Calcinosis)

### ***What is this problem?***

Calcium deposits in the skin have a variety of causes, usually of minor significance in the young but indicating serious disease in some older animals.

**Calcinosis circumscripta** is deposits of calcium at bony prominences or in the footpads and mouth. It is usually a disease of large dog breeds and occurs before two years of age.

**Calcinosis cutis** is induced by local damage in susceptible animals. The cause may be either dystrophic (local factors only causing damage leading to calcification) or metastatic (too high a concentration of calcium in the blood leading to deposits of calcium in the locally damaged tissues). In the latter case, there may be multiple calcium deposits.

### ***What do we know about the cause?***

The reason why a particular pet may develop this, or any cancer, is not straightforward. Cancer is often seemingly the culmination of a series of circumstances that come together for the unfortunate individual.

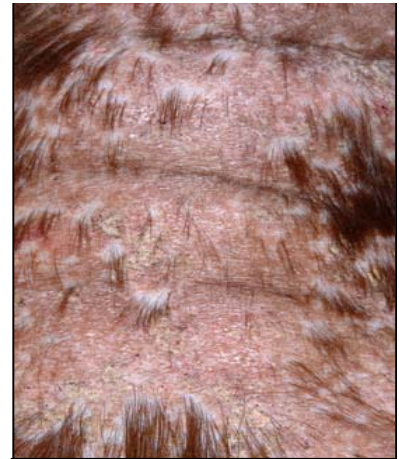
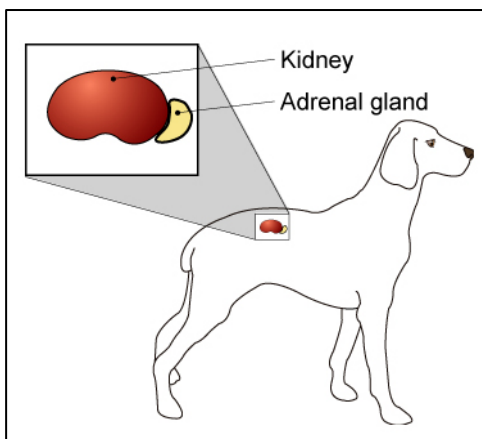


Image courtesy of Jan Hall,  
BVM&S, MS, MRCVS, DipACVD,  
Clinical Dermatology,  
Ontario Veterinary College

The cause of calcinosis circumscripta is unknown but there is often a genetic component. The most probable immediate cause is an increase in the blood enzyme lipase leading to degeneration of the subcutaneous adipose tissue followed by calcification.

Dystrophic causes of calcinosis cutis include idiosyncratic reactions to injections and other foreign materials.

The most common cause of metastatic calcinosis cutis in dogs is overproduction of adrenal hormones (corticosteroids or "steroids"). This may be due to overgrowth or cancer of the adrenal glands, or of the pituitary, the gland that controls the adrenals. Some cases are due to therapeutic use of steroid hormones to control other diseases, particularly pruritic (itchy) skin diseases and arthritic pain. Some dogs are more susceptible to the effects of excess steroid hormones than others.

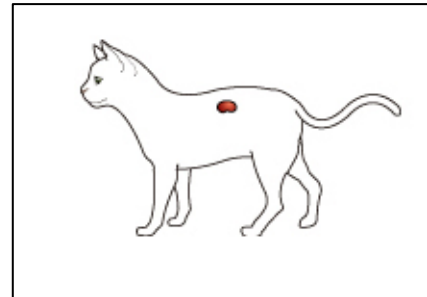


Other, but rarer, causes of metastatic calcification include kidney disease (this is the most common

cause in cats), malignant tumors producing abnormal hormones that increase blood calcium concentrations (e.g. tumors of the lymphoid system and glands of the anal sac), diabetes mellitus and lung disease. Occasionally it is recorded after some types of progesterone (female sex hormone) treatment. Occasionally puppies may have calcium deposition during serious illness but these deposits disappear spontaneously.

### ***Why has my pet developed this disease?***

Some animals have a greater tendency (genetic susceptibility) to calcium deposition. Calcinosis circumscripta is a disease of large dog breeds. It is probably familial and may be inherited in the German Shepherd dog as litter mates may develop the same disease. Calcinosis cutis develops in some animals but not others even though they have similar steroid hormone or blood calcium concentrations. Most animals have an underlying disease.



### ***Are these common tumors?***

These conditions are uncommon in dogs and rare in cats. Calcinosis cutis is most common in connection with adrenal hormone problems, including those of treatment with the hormones. The most common cause in cats is kidney disease.

### ***How will this problem affect my pet?***

The most obvious effect is hard lumps in the skin, footpads or mouth. These often ulcerate and discharge chalky material and pus.

Calcinosis cutis due to overactivity of adrenal hormones may be associated with loss of body muscle and swelling of the abdomen due to laxity of the muscles. There may be hair loss and comedones (black-heads). If the primary disease is malignant cancer or kidney disease, there may be severe weight loss.

### ***How is this problem diagnosed?***

Clinically, calcium deposits are often suspected, particularly when the age, breed and clinical history are considered.

Blood tests can help indicate some underlying primary conditions but it may be necessary to obtain a sample of the calcified area. The tissue samples are submitted for microscopic examination. Cytology (the microscopic examination of cell samples) is not useful for these conditions, so histopathology (the microscopic examination of specially prepared and stained tissue sections) is used. This is done at a specialized laboratory where the slides are examined by a veterinary pathologist. The piece of tissue may be a small part of the mass (biopsy) or the whole lump. Histopathology also rules out local cancers.

### ***What types of treatment are available?***

The usual treatment for calcinosis circumscripta and single areas of calcinosis cutis is surgical removal. Additional treatment for calcinosis cutis will depend on the underlying cause.

### ***Can this problem disappear without treatment?***

Small deposits may be resorbed. Larger deposits may be spontaneously pushed out through the skin. This may be very unpleasant with discharge and poor healing so some areas are best removed surgically.

### ***How can I nurse my pet?***

Preventing your pet from rubbing, scratching, licking or biting the problem areas will reduce itching, inflammation, ulceration, infection and bleeding. Any ulcerated area needs to be kept clean.



After surgery, the operation site similarly needs to be kept clean and your pet should not be allowed to interfere with the site. Any loss of sutures or significant swelling or bleeding should be reported to your veterinarian. If you require additional advice on post-surgical care, please ask.

### ***How will I know if the problem is permanently cured?***

'Cured' has to be a guarded term in dealing with any cancer.

This depends on the primary cause and the ability to eliminate it.

Single lumps due to causes such as trauma will be cured surgically. Calcinosis circumscripta is inclined to local recurrence, especially in the tongue, but the lesions usually cease development at maturity (approximately two years of age).

Calcinosis cutis may get worse before it gets better as the calcified tissue is pushed out through the skin. Cure will usually depend on resolution of the primary illness, which, sadly, is not always possible.

### ***Are there any risks to my family or other pets?***

No, these are not infectious problems and are not transmitted from pet to pet or from pets to people.